

Clinical & Refractive Optometry is pleased to present this continuing education (CE) article by Dr. Ron Melton and Dr. Randall Thomas entitled **Dacryocystitis**. In order to obtain a 1-hour Council of Optometric Practitioner Education (COPE) approved CE credit, please refer to page 86 for complete instructions.

Dacryocystitis

Ron Melton, OD; Randall Thomas, OD

SUBJECTIVE

A 58-year-old white male presents with mild pain and tenderness to the nasal aspect of the right lower eyelid and periorbital area near the nose. Three days ago, he noticed some irritation in the inner corner of the right eye with occasional tearing, which has gradually worsened. For the last two days, he has also noticed a mild mucous drainage from the right eye. He has no complaint about the vision being involved. The patient is afebrile and has been feeling fine except for the recent discomfort to the right eye. He is taking propranolol (Inderal) for hypertension and is allergic to erythromycin.

OBJECTIVE

- Visual acuity is OD 6/9 (20/30), OS 6/9 (20/30)
- Gross observation: mild erythema and edema to the right inferior eyelid and periorbital tissue with the innermost aspect of the lower eyelid showing mild swelling (Fig. 1)
- Lids: 1+ dermatochalasis superiorly right and left; 1+ erythema and edema right lower lid and nasal periorbital area over the lacrimal sac; right lower lid margin and lashes have mild whitish, mucous exudate (Fig. 2); palpation of the area over the lacrimal sac expresses a mucoid discharge (Fig. 3) that collects on the right lower lid margin (Fig. 4); patient describes mild pain to the area palpated
- Bulbar conjunctivae: 1+ hyperemia OD
- Cornea: slight inferior superficial punctate keratitis OD; OS clear
- Anterior chamber: clear with no cell/flare
- Tension by applanation (TA): 15/15 at 10:45 a.m.
- Internal: 0.25 cup-to-disc ratio (C/D) OU with maculas clear, retinal blood vasculature normal OU

R. Melton, R. Thomas — Adjunct faculty members at the Pennsylvania, Pacific University and SUNY Colleges of Optometry; Consultants to the American Optometric Association and Fellows of the American Academy of Optometry; both are in clinical practice in North Carolina. Recipients of the Glaucoma Educators of the Year Award presented by the American Academy of Optometry.

ASSESSMENT

Acute right dacryocystitis

PLAN

- Warm compresses followed by gentle massage to the lacrimal sac area b.i.d.
- Moxifloxacin (Vigamox) q.i.d. OU
- Started patient on amoxicillin and clavulanate (Augmentin) 875 mg b.i.d. p.o. x 1 week
- Recommend follow-up in 2 days

Follow-up 2 days:

- Patient has noticed slightly less tenderness to the lacrimal sac area with less mucous drainage from the right eye. There is no expression of mucoid exudate on palpation of the right lacrimal sac area. Mild fluorescein pooling is seen in the right eye when compared to the left inferior lacrimal lake, indicating that the right inferior nasolacrimal drainage system is still somewhat stenosed. The patient is to continue the warm compresses, massage, Vigamox, and Augmentin as instructed on day one and be rechecked in 5 days.

Follow-up 7 days (5 days from last check):

- Significant improvement is observed with the patient stating there is no tenderness to the right lacrimal sac area and no discharge from the right eye. Clinically, there is no discharge seen on palpation of the right lacrimal sac and no complaint of tenderness. Instillation of fluorescein reveals no abnormal pooling of the dye. The patient is on his last day of Augmentin. He is directed to continue the Vigamox b.i.d. x 4 more days and to continue the warm compresses daily for 1 week. He is educated of the possibility of recurrence of the problem. He is to schedule a complete eye examination in 1 month as his last complete eye check was 2 years ago.

Comments: This is a fairly straightforward case of a mild dacryocystitis. Because of this, smears and cultures of the expressed mucous exudate were not obtained. In moderate to severe cases, the clinician should be more

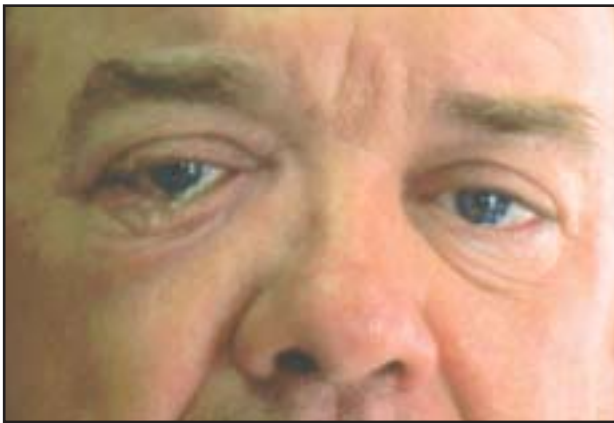

Fig. 1 This patient presents with mild erythema and edema to the right inferior eyelid and periorbital tissues. The innermost aspect of the lower eyelid shows mild swelling and tenderness on palpation.

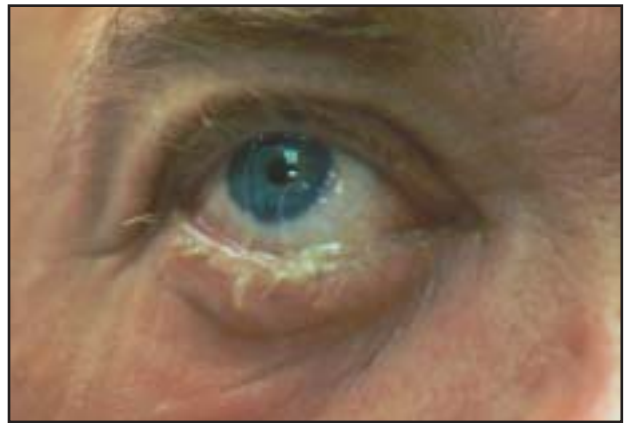


Fig. 2 There is a mild whitish, mucous exudate at the right lower lid margin and on the right lower lashes

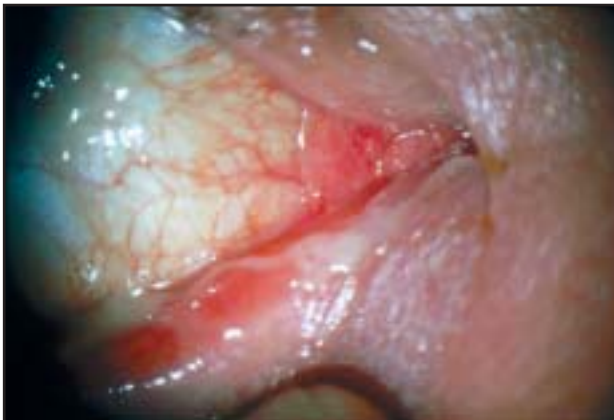

Fig. 3 Palpation of the right lacrimal sac expresses a mucoid discharge from the inferior punctae

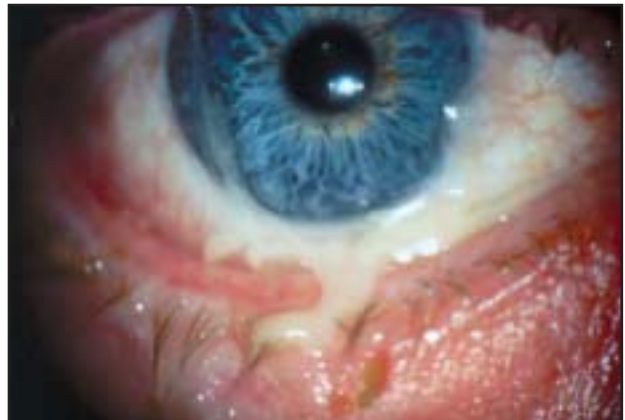

Fig. 4 A moderate mucoid discharge collects on the right lower lid following expression from the lacrimal sac

aggressive, obtaining culture and sensitivity testing and the systemic antibiotic should be continued for 10 to 14 days. One should not wait for the culture results to begin treatment, as there can be a 3- to 4-day delay in obtaining results.

Augmentin is a combination antibiotic (amoxicillin/clavulanic acid) with a broad spectrum of activity. Amoxicillin, a synthetic penicillin, is readily inactivated by the enzyme penicillinase. Many staphylococcal species produce this enzyme. Clavulanic acid inactivates B-lactamase enzymes commonly found in microorganisms resistant to penicillin. Therefore, the combination of amoxicillin/clavulanic acid extends the antibiotic spectrum of amoxicillin to include bacteria normally resistant to amoxicillin.

Alternatives to the Augmentin for the treatment of dacryocystitis include dicloxacillin (a synthetic penicillinase-resistant synthetic penicillin) or a cephalosporin such as

cephalexin (Keflex), cefaclor (Ceclor), or cefuroxime (Ceftin). Keep in mind that the cephalosporins share some potential cross-allergenicity with the penicillins, so if a patient indicates a true past history of a penicillin allergy, then stay away from prescribing the cephalosporins. Rather, consider levofloxacin (Levaquin) or erythromycin. The proper dosing of the particular systemic antibiotic is confusing and difficult to keep straight. For this reason, keeping a current "Drug Facts and Comparisons" (published by Lippincott Williams & Wilkins) in the office allows for an excellent reference to find information on the systemic medicines and their proper dosage for a specific condition.

Dacryocystitis is one of many eye diseases that require the use of systemic medications for proper management. It is incumbent on our profession to accept the challenge of mastering the systemic medications in order that we may be better able to fulfill the role of primary eye care providers in the future.

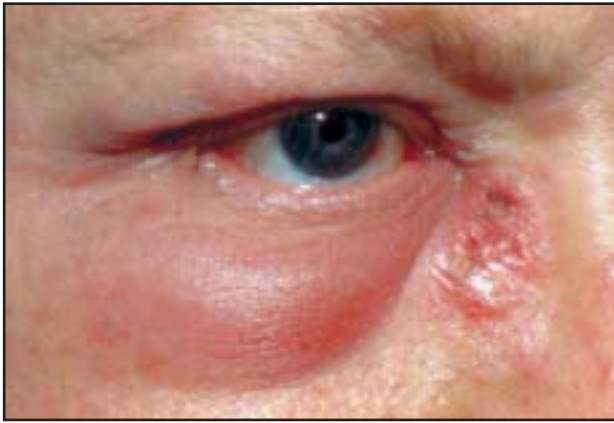


Fig. 5 In more severe cases of dacryocystitis, an abscess may form over the lacrimal sac requiring incision, drainage, and systemic antibiotics

GENERAL OBSERVATIONS

- Inflammation of the lacrimal sac
- More common in Caucasian women over age 40, but can be at any age
- Multiple mechanisms can cause stenosis or occlusion of the nasolacrimal system setting the stage for bacterial proliferation and clinical infection
- Most common pathogens are staphylococci, *Streptococcus pneumoniae*; less commonly, *Haemophilus influenzae*, *Pseudomonas aeruginosa*, and *Proteus mirabilis*

Symptoms/Signs

- Pain, tenderness, and redness over the lacrimal sac
- Possible discharge (expressed from punctum with applied pressure) and tearing
- If associated fever, must be treated more aggressively
- May be recurrent
- Lacrimal sac cyst or mucocele possible in chronic cases
- In more severe cases, abscess may form over lacrimal sac (Fig. 5) requiring incision, drainage, and systemic antibiotics

Differential Diagnosis

- Canalculitis, facial cellulitis, acute ethmoid or frontal sinusitis

Work-up

- If moderate to severe symptoms/signs, work-up includes smears and cultures (gram stain, blood agar; also chocolate agar in children) of discharge
- CT of orbit and paranasal sinuses if atypical or severe; or if nonresponsive

Therapy

Goal is to control inflammation/infection and maintain patency of nasolacrimal duct:

- Warm compresses over the site of infection followed by gentle massage (tenderness may prevent this step)
- Topical broad spectrum antibiotic drops q.i.d. (aminoglycoside, trimethoprim/polymyxin combination, or fluoroquinolone)
- Systemic antibiotic such as dicloxacillin or amoxicillin with clavulanate (Augmentin); or a cephalosporin such as cephalexin (Keflex), cefaclor (Ceclor), or cefuroxime (Ceftin)
- Oral analgesics such as acetaminophen (with or without codeine) or ibuprofen 400 mg up to q.i.d. (comparable to acetaminophen/codeine combination, such as the legendary Tylenol #3 narcotic analgesic).
- Surgical correction with dacryocystorhinostomy (DCR) in chronic or recurrent cases
- If febrile and acutely ill, hospitalize with I.V. antibiotics

Prognosis

Usually excellent; in older, debilitated patients, orbital cellulitis can be a complicating secondary occurrence.

Disclaimer: Not every detail of every case is discussed, rather the key clinical findings are described. For example, if nothing is said about the corneal status, you should assume that the cornea is normal, etc. When vision is recorded, it should be assumed to be best corrected or pinholed. Regarding therapy, we show how we treated the particular case. Given that medicine is an art, as well as a science, therapy will — and often does — vary with each unique patient presentation depending on severity, known drug allergies, prior treatment, response to therapy, etc.

INSTRUCTIONS FOR CE CREDITS

In order to obtain a 1-hour COPE-approved CE credit, please follow these steps:

- Fill in the identification section and answer the 10 multiple choice questions in this CE credit application form
- Prepare a cheque for \$25.00 made out to Medicconcept
- Mail your completed CE credit application form and cheque to the Journal at: *Clinical & Refractive Optometry*, 3333 Cote Vertu Blvd., Suite 300, St. Laurent, Quebec H4R 2N1

Your answers will be sent for marking to the School of Optometry, University of Montreal, Quebec. If you score 70% or more, a COPE-approved CE Credit Certificate will be issued by the University of Montreal and *Clinical & Refractive Optometry* for your records and display in your office.

IDENTIFICATION

Name: First _____ Last _____

Address: _____
Number Street Suite

_____ City Province Postal Code

Office Phone: () _____ Fax: () _____ e-mail: _____

Registration Number: _____

QUESTIONNAIRE

Dacryocystitis

Ron Melton, OD; Randall Thomas, OD

- Which one of the following is **NOT** associated with dacryocystitis?
 - Mild erythema and edema to the inferior eyelid
 - Mild swelling of the innermost aspect of the lower eyelid
 - Occasional tearing
 - Loss of visual acuity
- Which one of the following was **NOT** part of therapy in this case?
 - Gentle massage to the lacrimal sac area b.i.d.
 - Treatment with erythromycin ophthalmic ointment q.i.d. OD
 - Warm compresses
 - Moxifloxican (Vigamox) q.i.d. OU
- Which of the following statements is **FALSE**?
 - At follow-up 5 days, significant improvement was observed
 - At follow-up 7 days, there was no complaint of tenderness
 - Fluorescein pooling may appear in cases of dacryocystitis
 - Mild, whitish, mucous exudates is a sign of the condition
- In the Case Report, which of these signs and symptoms were present?
 - 1+ dermatochalasis superiorly right and left
 - Mild whitish, mucous exudates on right lower lid margin and lashes
 - Mild pain upon palpitation
 - All of the above

5. Which of the following is a possible recommended therapy for dacryocystitis?
 - Systemic antibiotic such as dicloxacillin
 - Amoxicillin with clavulanate (Augmentin)
 - Cephalosporin such as cephalexin (Keflex)
 - All of the above

6. Which of the following statements is **FALSE**?
 - Dacryocystitis occurs more commonly in Caucasian men over age 40
 - Most common pathogens are staphylococci and *Streptococcus pneumoniae*
 - Dacryocystitis may be recurrent
 - More severe cases may require incision and drainage

7. Which of the following is **NOT** part of differential diagnosis in dacryocystitis?
 - Canaliculitis
 - Facial cellulitis
 - Blepharitis
 - Acute ethmoid or frontal sinusitis

8. Which one of the following is **FALSE**?
 - In moderate to severe cases, the systemic antibiotic should be continued for 7 to 10 days
 - In the Case Report, the patient history was positive for hypertension
 - Amoxicillin is readily inactivated by the enzyme penicillinase
 - Cephalosporins are not recommended in the presence of penicillin allergy

9. The goal of therapy includes all of the following **EXCEPT**:
 - Elimination of the possibility of recurrence
 - To control inflammation/infection
 - To maintain patency of nasolacrimal duct
 - To control patient discomfort through the use of oral analgesics if needed

10. Which of the following is **FALSE**?
 - Multiple mechanisms can cause stenosis or occlusion of the nasolacrimal system
 - Lacrimal sac cyst or mucocele are possible in chronic cases
 - In older, debilitated patients, orbital cellulitis can be a complicating secondary occurrence
 - Haemophilus influenzae* is a common pathogen in dacryocystitis