

Clinical & Refractive Optometry is pleased to present this continuing education (CE) article by Dr. Ron Melton and Dr. Randall Thomas entitled **Amiodarone Keratopathy**. In order to obtain a 1-hour Council of Optometric Practitioner Education (COPE) approved CE credit, please refer to page 124 for complete instructions.

Amiodarone Keratopathy

Ron Melton, OD; Randall Thomas, OD

SUBJECTIVE

A 58-year-old white male presented complaining of slightly reduced distance vision and a slight haziness to his vision, which he had noticed over the past six months. The medical history is significant in that he had had a myocardial infarction (MI) in 1987 with a subsequent MI in 1991. One year ago, he was placed on 600 mg per day of amiodarone (Cordarone — Wyeth-Ayerst). Other medications included Procardia 10 mg t.i.d., Sorbitrate SA 40 mg t.i.d., Captopril 20 mg b.i.d., Klotrix 10 mg b.i.d., Maxzide 1 per day, Zylprim 100 mg per day, Digoxin 0.25 mg per day, Nitrostat 1/100th grams per mg p.r.n. The patient had no known drug allergies. The ocular history revealed that at his last eye exam, one and a half years ago, his ocular health was normal. There was no personal or family history of glaucoma, cataracts, or blindness.

OBJECTIVE

- The presenting vision was OD: 6/9 (20/30), J2; OS: 6/9 (20/30) -1, J2
- External examination showed the pupils OD: 4 mm; OS: 4 mm; round, reactive to light and accommodation
- No Marcus-Gunn pupil was observed
- Extraocular muscle function was full and smooth
- Confrontation visual fields were full in each eye
- Computerized automated perimetry with the Humphrey central 76 screening test was normal OU
- Manifest refraction was OD: pl -2.00 x 101 (6/6-2); OS: +0.25 -2.50 x 80 (6/7.5)
- A near add of +2.00 in each eye gave a best visual acuity of OD (J1); OS (J1)
- Pinhole testing showed no improvement of the above best visual acuity

R. Melton, R. Thomas — Adjunct faculty members at the Pennsylvania, Pacific University and SUNY Colleges of Optometry; Consultants to the American Optometric Association and Fellows of the American Academy of Optometry; both are in clinical practice in North Carolina. Recipients of the Glaucoma Educators of the Year Award presented by the American Academy of Optometry.

- Biomicroscopy revealed the conjunctivas to be white and quiet OU
- The corneas OU showed light brown microdeposits in a horizontally linear pattern (Figs. 1, 2)
- The deposits are concentrated on the inferior third of the cornea with aborizations extending superiorly
- The whorl-like verticillate pattern occasionally crosses the visual axis and appear slightly more concentrated in the left cornea (Fig. 3)
- Slit-lamp evaluation with optic section view shows the deposits to be in the epithelial layer of the cornea (Fig. 4)
- There is no positive staining pattern of the corneas either eye with fluorescein or rose bengal dye
- The angles appeared open and the anterior chamber quiet in each eye
- The lens was clear OU
- Intraocular pressures with Goldmann applanation tonometry was 14 OU
- A dilated fundus examination showed the optic nerve heads to be healthy OU with good color, contour, and distinct disc margins
- The cup-to-disc ratio was .1H/.1V in each eye
- The macular area was healthy OU
- The blood vasculature presented with a normal course OU
- The peripheral retina was entirely healthy in each eye

ASSESSMENT

- Amiodarone keratopathy OU

PLAN

- The plan for this patient included an optional prescription change. He decided to make the change based on a trial frame comparison of the new prescription with his present correction
- Anterior segment 35 mm slide photographs of both corneas were taken for documentation, so that comparisons could be made at a follow-up evaluation in six months time (or sooner if any visual problems were noticed)
- A letter communicating the eye examination findings was sent to the patient's cardiologist

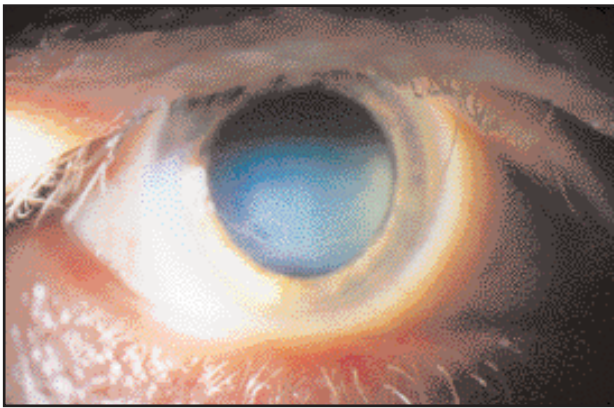


Fig. 1 The OD cornea shows light brown microdeposits in a horizontally linear pattern.

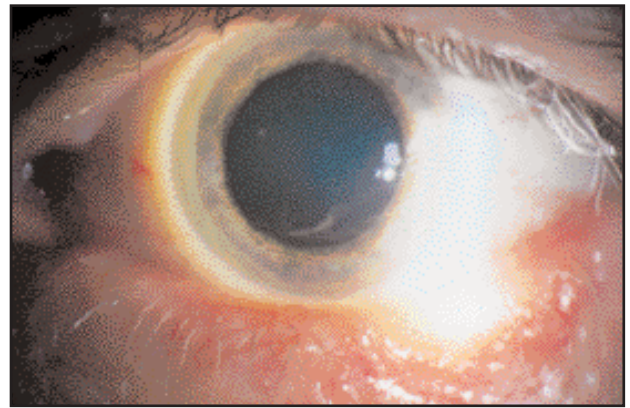


Fig. 2 The OS cornea shows similar but slightly more concentrated light brown, linear, horizontal microdeposits compared to the OD cornea.

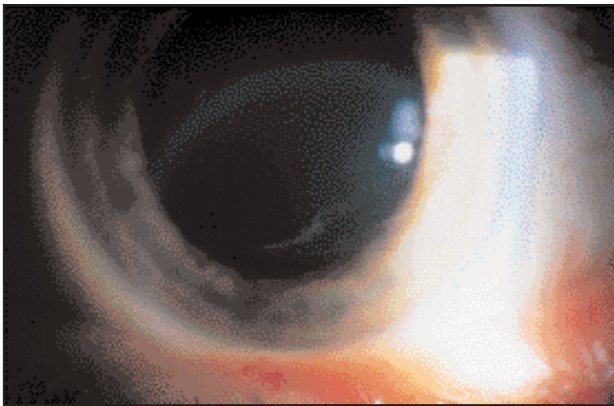


Fig. 3 A closer view of the OS cornea reveals deposits concentrated in the inferior third of the cornea with aborizations extending superiorly.

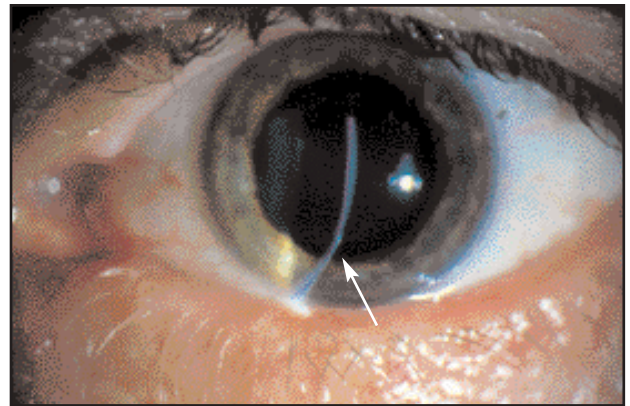


Fig. 4 Slit-lamp evaluation with optic section view helps to show the deposits to be in the epithelial layer of the cornea.

Comments: Amiodarone (Cordarone) is a benzofuran derivative that is used for the treatment of documented life-threatening recurrent ventricular fibrillation when other antiarrhythmics are inadequate or intolerable. The drug activity prolongs the duration of myocardial action potential, depresses sinus node function, and is a non-competitive alpha and beta sympathetic receptor-blocking agent. Clinically, its activity prevents the recurrences of ventricular fibrillation or sustained ventricular tachycardia.

Amiodarone is extremely lipid-soluble and accumulates extensively in tissues. Systemic administration results in concentrations of the drug in the lamellar bodies in corneal, conjunctival, and intraorbital tissues.

The drug is normally instituted in a hospital setting — a loading dose of 800 to 1600 mg per day is given for up to three weeks, which is then tapered to a maintenance dose of 400 mg per day. It is important to monitor pulmonary, hepatic, and thyroid function with long-term

therapy because of adverse side effects. Pulmonary toxicity is the most severe adverse side effect, with about a 10% mortality rate.

Ocular abnormalities are almost always found with long-term amiodarone use. Patients on amiodarone in normal doses get corneal microdeposits (Fig. 5) which can persist for months after the drug has been discontinued. The corneal keratopathy that is seen is categorized into three stages: mild, moderate, or advanced. In the mild form, the corneal deposition reveals bilateral, light brown epithelial deposits in a horizontally linear branching pattern, normally at the inferior third of the cornea. In the moderate stage, horizontal and aborizing lines that curve superiorly are seen. In the advanced stage, a whorl-like deposition is found, usually located in the lower third of the epithelium. This verticillate pattern can cross the visual axis and create symptoms of photophobia, halos, and blurred vision.

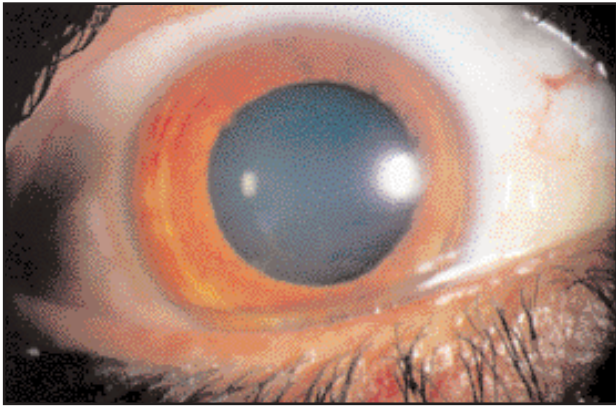

Fig. 5 This case reveals the inferior whorl-like verticillate pattern encroaching through the visual axis.

Corneal involvement is directly related to the dosage and duration of amiodarone therapy. The corneal deposits normally occur within four months of treatment institution. Patients taking 100 to 200 mg of amiodarone have been found to have minimal or no corneal deposits, while most patients on 400 mg of therapy develop dyscorneal abnormality. When this drug is discontinued, the corneal deposits regress until they eventually disappear.

The mechanism for the corneal deposits is felt to be a lysosomal disorder created by the drug. Amiodarone is an amphiphilic drug which collects within lysozymes in the epithelium, thus causing the corneal changes. Similar corneal verticillata have been seen in patients on phenothiazines, chloroquine, and endomethacin.

There have also been reported cases of optic neuropathy as ocular side effects to amiodarone use. The fundusoscopic appearance in patients is similar to that seen in ischemic optic neuropathy, with segmental disc swelling and hemorrhages. With discontinuation or regression of the dosage of amiodarone, the papillopathy was seen to improve.

GENERAL OBSERVATIONS

- The case that was presented gives a classic illustration of the mild to moderate corneal verticillate deposition that occurs with prolonged amiodarone therapy. It is important to communicate the clinical information that is collected to the patient's internist or cardiologist
- Should the vision be affected in a serious manner, then it becomes a dilemma of whether or not to decrease or discontinue therapy. Fortunately, the visual acuity is usually not affected in a serious manner and this decision can be averted
- It would be an optimum clinical situation to be able to obtain baseline visual acuities, visual fields, fundus photography, and anterior segment photography on patients started on this medication. Then these patients could be monitored on a regular basis for ocular health changes. Communicating this information to the prescribing physician could open the door for better relationships in the medical community.

Disclaimer: Not every detail of every case is discussed, rather the key clinical findings are described. For example, if nothing is said about the corneal status, you should assume that the cornea is normal, etc. When vision is recorded, it should be assumed to be best corrected or pinholed. Regarding therapy, we show how we treated the particular case. Given that medicine is an art, as well as a science, therapy will — and often does — vary with each unique patient presentation depending on severity, known drug allergies, prior treatment, response to therapy, etc.

INSTRUCTIONS FOR CE CREDITS

In order to obtain a 1-hour COPE-approved CE credit, please follow these steps:

- Fill in the identification section and answer the 10 multiple choice questions in this CE credit application form
- Prepare a cheque for \$25.00 made out to Medicconcept
- Mail your completed CE credit application form and cheque to the Journal at: *Clinical & Refractive Optometry*, 3333 Cote Vertu Blvd., Suite 300, St. Laurent, Quebec H4R 2N1

Your answers will be sent for marking to the School of Optometry, University of Montreal, Quebec. If you score 70% or more, a COPE-approved CE Credit Certificate will be issued by the University of Montreal and *Clinical & Refractive Optometry* for your records and display in your office.

IDENTIFICATION

Name: First _____ Last _____

Address: _____
Number Street Suite

_____ City Province Postal Code

Office Phone: () _____ Fax: () _____ e-mail: _____

Registration Number: _____

QUESTIONNAIRE

Amiodarone Keratopathy

Ron Melton, OD; Randall Thomas, OD

- Which of the following statements about amiodarone keratopathy is **TRUE**?
 - Computerized automated perimetry with the Humphrey central 76 screening test is usually abnormal
 - Fluorescein or rose bengal dye often reveals a staining pattern of the corneas
 - In this case, the peripheral retina was entirely healthy in each eye
 - It is always accompanied by elevated intraocular pressure
- Which of the following statements about amiodarone keratopathy is **FALSE**?
 - It is sometimes associated with reduced distance vision
 - Light brown microdeposits are present in a horizontally linear pattern
 - The microdeposits appear in the epithelial layer of the cornea
 - It is exacerbated by the presence of cataracts
- Which of the following does **NOT** describe the signs and symptoms occurring in this case?
 - Night vision was reduced in both eyes
 - The conjunctivas were shown to be white and quiet through biomicroscopy
 - The anterior chamber was quiet in each eye
 - The optic nerve appeared to be healthy OU
- All of the following describe the course of action taken, **EXCEPT**:
 - Optional prescription change, which the patient made
 - Anterior segment 35 mm slide photographs were taken of both corneas for follow-up use
 - A letter communicating the eye examination findings was sent to the patient's cardiologist
 - The amiodarone dosage was reduced

5. All of the following statements about amiodarone are true, **EXCEPT**:
- The drug activity prolongs the duration of myocardial action potential
 - It is used as first-line therapy for documented life-threatening recurrent ventricular fibrillation
 - It is a non-competitive alpha and beta sympathetic receptor-blocking agent
 - Systemic administration results in drug concentration in the lamellar bodies in corneal, conjunctival, and intraorbital tissues
6. Which of the following statements about amiodarone-related ocular abnormalities is **FALSE**?
- They are almost always found with long-term use of the drug
 - Corneal involvement is directly related to drug dosage and duration of therapy
 - Corneal deposits normally occur within four months of treatment institution
 - The abnormalities appear immediately upon cessation of the drug
7. The following statements characterize corneal keratopathy, **EXCEPT**:
- It occurs in three stages: mild, moderate, or advanced
 - In the advanced stage, a whorl-like deposition is found, usually in the lower third of the epithelium
 - This verticillate pattern can create symptoms of photophobia
 - In the mild form, the corneal deposits are usually unilateral
8. Which of the following statements is **FALSE**?
- Patients taking 50 to 100 mg of amiodarone traditionally have minimal or no corneal deposits
 - Most patients on 400 mg of therapy develop dyscorneal abnormality
 - Optic neuropathy can be an ocular side effect to amiodarone use
 - Ischemic optic neuropathy is characterized by segmental disc swelling
9. All of the following statements are true, **EXCEPT**:
- The case presented was a classic illustration of advanced corneal verticillate deposition
 - In amiodarone keratopathy, visual acuity is usually not affected in a serious manner
 - Optimally, baseline visual acuities, visual fields, fundus photography, and anterior segment photography would be obtained on patients started on amiodarone
 - It is important to obtain information on personal and family history, as well as drug allergies
10. An effective treatment plan for amiodarone keratopathy includes the following, **EXCEPT**:
- Communication of the clinical information to the patient's internist or cardiologist
 - Follow-up evaluation of the condition in six months time
 - Monitoring on a regular basis for ocular health changes
 - Use of an eye patch on alternating eyes to reduce strain